



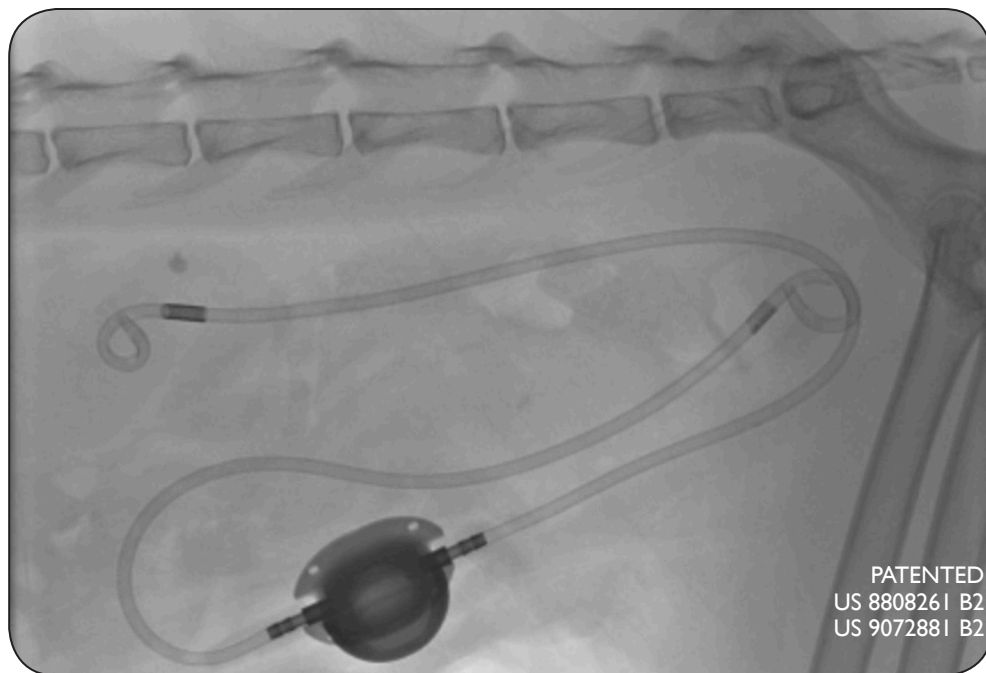
Specialty Medical Devices For The Veterinary Community

the SUB™ 2.0

A Subcutaneous Ureteral Bypass System

A SURGICAL GUIDE

provided by Drs. Allyson Berent and Chick Weisse



*The **Improved** Therapeutic Option for Dogs & Cats
to Bypass Ureteral Obstructions
designed and developed in collaboration with veterinarians*

the
SUB™
Veterinary Use Only

For Technical Information, please contact:

Allyson Berent, DVM, DACVIM
allyson.berent@gmail.com

Chick Weisse, VMD, DACVS
chick.weisse@gmail.com

For Product Information, please contact:

info@norfolkvetproducts.com

Norfolk Vet Products Inc.
7350 North Ridgeway Avenue, Skokie, Illinois 60076 USA
Tel: 847.674.7143 • Fax: 847.674.7066

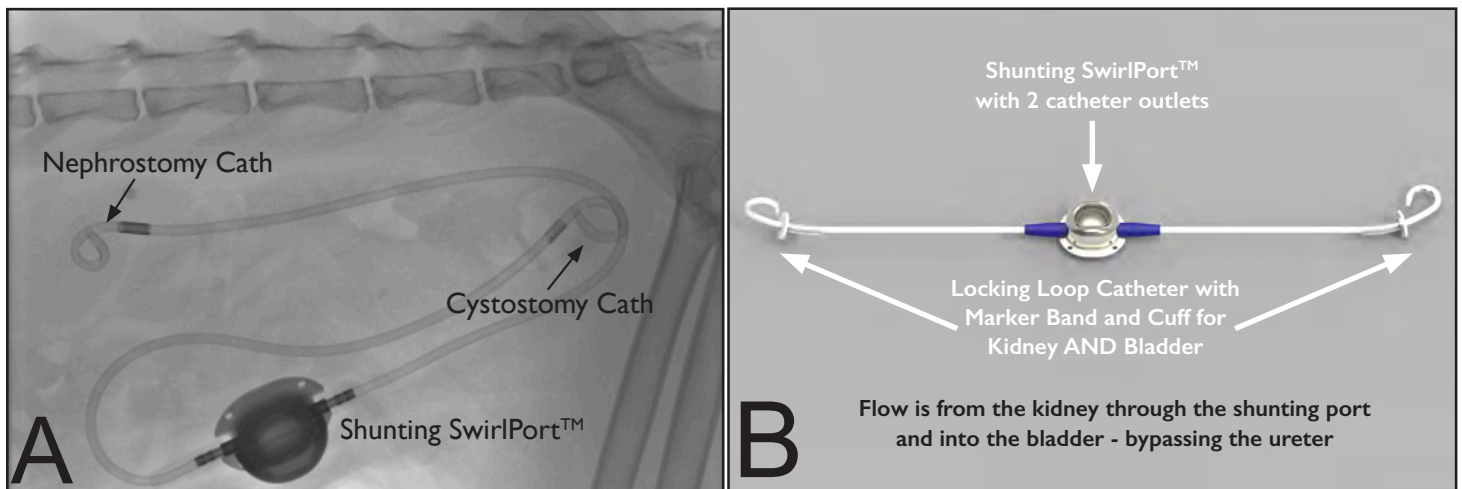
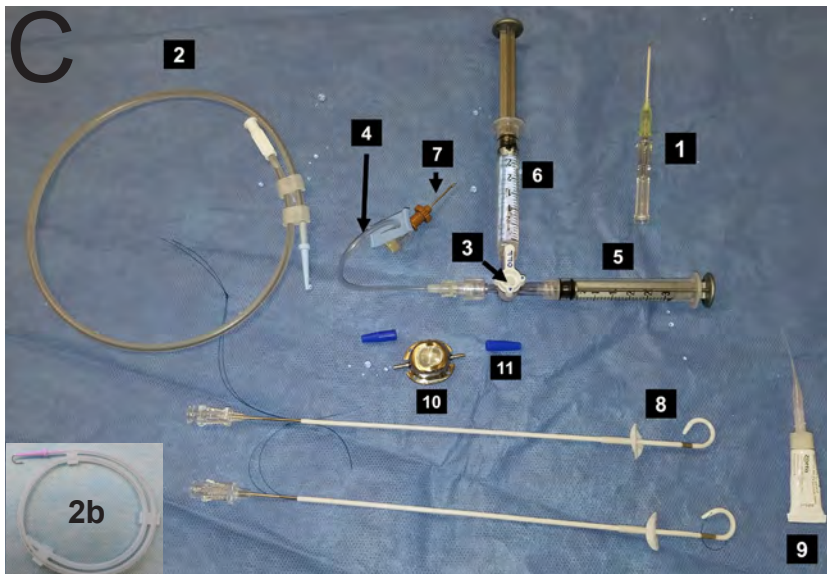


Figure I: The Subcutaneous Ureteral Bypass (SUB™) device.

- A) Lateral fluoroscopic image of a cat patient after SUB™ placement showing the nephrostomy catheter, cystostomy catheter, and shunting subcutaneous injection port.
- B) The SUB™ device put together outside of the patient.

EQUIPMENT NEEDED



SUB™ KIT CONTENTS

SUB2-2001K - for use in cats and small dogs

- 1 x Shunting SwirlPort w/ Catheter Securement Boots
- 2 x 6.5F x 20cm Locking Loop Catheter w/Hollow cannula
- 1 x 0.035" x 45cm J-tip Guidewire
- 2 x 22G Posi-Grip Huber Needles
- 1 x 22G Huber Needle Infusion Set
- 1 x 18G Over-the-Needle Catheter
- Accessories (extra boots, cuff, and sleeve)
- Surgical Instructions

SUB2-2002K - for use in larger dogs

- Same as SUB2001K, but with:
- 2 x 6.5F x **35cm** Locking Loop Catheter w/Hollow cannula

Figure I C: Parts of the SUB™ device & equipment needed for placement

1. 18G over-the-needle catheter - included in the SUB Kit.
2. 0.035" x 45cm J-tip Guidewire (see 2b) - included in the SUB Kit.
3. 3-Way Stop-cock (part of SUB Flush Kit) - **NOT INCLUDED** in the SUB Kit. *Cat. No. SFK-22*
4. T-Port for pyelogram and SUB device flushing (part of SUB Flush Kit) - **NOT INCLUDED** in the SUB Kit. *Cat. No. SFK-22*
5. 3mL Syringe (part of SUB Flush Kit) - **NOT INCLUDED** in the SUB Kit. *Cat. No. SFK-22*
6. 3mL Syringe with 50% Contrast - **NOT INCLUDED** in the SUB Kit.
7. 22G non-coring Huber point Needle - included in the SUB Kit.
8. 2 x 6.5F Locking Loop Catheters (kidney and bladder) with Dacron Cuff and Silicone Sleeve w/hollow Cannula. The hollow cannula goes over the guidewire during installation. There is a black radiopaque marker band proximal to the fenestrations to ensure no leaking - included in the SUB Kit.
9. Cyanoacrylate Tissue Glue - **NOT INCLUDED** in the SUB Kit. *Cat. No. GLU*
10. Shunting SwirlPort™. This should be flushed with saline using a Huber point needle to ensure patency of both ends prior to implantation - included in the SUB Kit.
11. Blue Boots for catheter securement to port - included in the SUB Kit.

a guide to the use of:

the SUB™ 2.0

A Subcutaneous Ureteral Bypass System

An Improved Therapeutic Option for Dogs & Cats Designed and Developed in Collaboration with Veterinarians

GUIDELINES WHEN USING THE SUBCUTANEOUS URETERAL BYPASS (SUB™)

provided by Allyson Berent, DVM, DACVIM and Chick Weisse, VMD, DACVS

The development of an indwelling SUB device (**Figure 1**) using a combination locking-loop nephrostomy catheter attached via a dual-armed shunting SwirlPort™ to a multi-fenestrated locking-loop cystostomy catheter allows a nephrostomy tube to remain indwelling long-term.¹⁻⁴ A similar bypass device in humans has been used with extensive urinary tract malignancies, ureteral strictures secondary to renal transplantation, when ureteral stenting is ineffective, or when traditional surgery fails or is contraindicated.⁵⁻⁷ It has been shown to reduce complications associated with externalized nephrostomy tubes and improve quality of life. The SUB™ device was designed in 2009 for veterinary patients and has been used in thousands of cats to date. It contains a locking-loop design to prevent migration of the nephrostomy catheter, and a shunting port in the subcutaneous space that is used for flushing and sampling of urine as needed; a design unique to this system to help maintain long-term patency.

The use of the SUB™ device was reported in cats and dogs.¹⁻⁴ This device has been successfully placed and indwelling since 2009. The shunting port is secured to the ventral abdominal wall, connecting the nephrostomy and cystostomy catheters, creating an artificial ureter, while also allowing sampling and flushing of the urinary system. If there are concerns of patency, or the need for a culture from the renal pelvis, this can be easily obtained through this subcutaneous port using a non-coring Huber needle. This avoids the need for high-risk interventions or diagnostics. It is important for the operator to have appropriate training with this device prior to considering its use on a clinical patient. Please contact Norfolk Vet Products prior to use if you have any device related questions, and/or please contact Drs. Allyson Berent and Chick Weisse (Allyson.Berent@gmail.com or Chick.Weisse@gmail.com) if you have any procedural related questions. The details of the procedure are described in detail below. Practical training in highly recommended prior to using this device on a patient.

Complications (**Table 1; Pg 17**) encountered with this device are expanded upon at the end of this manual. Technical complications are uncommon and can often be avoided with proper training. This data is from a recent report in 174 SUBs placed in the authors' practice.¹ These complications include: 1) **leakage** at the nephrostomy/cystostomy tube exit or shunting port. This issue has been resolved with the addition of the Dacron cuff design to the renal capsule and bladder wall, respectively. The most common place for leakage is at the junction of the port and the catheter, where the locking string is secured. If this string is not properly trimmed, or at all exposed, leaking will occur. Please follow instructions below VERY carefully to avoid this; 2) **hemorrhage** during nephrostomy tube placement (<5%) can occur with renal pelvis trauma during wire or catheter manipulations or if you puncture through a renal vessel; 3) **system occlusion** with blood clots (5-8%), purulent debris (<1%), or stones (24% at a median of 463 days post-op; with the new recommendation of flushing the system through the shunting port routinely with tetra-EDTA [T-FloLoc™] every 3 months, occlusion of the catheter rarely occurs); 4) **kinking** of the catheter during or after placement (<1%); and 5) **UTIs** (seen 31% pre-op and 8% post-op). Most of these complications can be avoided with careful placement and thorough leak testing upon completion of the procedure (see below).

The use of a SUB device for feline and canine patients with a ureteral obstruction can be considered a functional option for the treatment of all causes of ureteral obstruction. There is far more information on its use in feline than canine patients to date, and ureteral stents are still considered a less invasive and highly effective treatment option for canine patients, in the authors' practice.⁸ The literature would support that this device is considered to have less short- and long-term complications in cats than all other alternatives when appropriate training is obtained.^{1-4,9-11} Care should be taken, as the longest device has been indwelling for 8.0 years, so outcomes beyond this point cannot be ascertained. Also, the reported literature with the highest number of cases and longest follow-up time is out of the authors' practice, documenting both a learning curve, and success with broader expertise.

A SURGICAL GUIDE TO THE SUB™ PROCEDURE

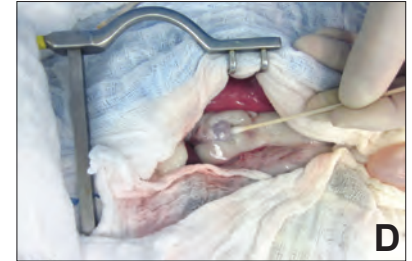
by Allyson Berent, DVM, DACVIM and Chick Weisse, VMD, DACVS

PREPARATION

Before proceeding with the surgery, each part of the system should be prepared by flushing the catheters, wires and port to ensure patency and to make sure each piece is moist. The catheters should be straightened out over the hollow cannulas.


THE LAPAROTOMY

A ventral midline laparotomy is performed in order to expose the bladder apex and the affected kidney. The peri-renal fat is gently and bluntly dissected off the caudal pole of the kidney exposing a 1-2 cm region of renal capsule (**Figure 1D, right**).



PLACING THE LOCKING LOOP NEPHROSTOMY CATHETER

The nephrostomy catheter should be prepared: The hollow cannula is placed inside the pre-flushed 6.5 French locking-loop catheter (pre-loaded with the Dacron cuff and silicone sleeve). The system should be flushed with sterile saline.



Locking Loop Nephrostomy Catheter

- A) Catheter with a hollow cannula prior to straightening. There is a radiopaque mark that allows the operator to observe the end of the last hole of the pigtail catheter under fluoroscopy.
- B) The hollow trocar is advanced, straightening the catheter, and placed over a guide wire (0.035").
- C) The hollow cannula is removed and the pigtail is made at the distal end of the catheter as the string is locked in place.

With the aid of fluoroscopy, the nephrostomy catheter is placed using the modified-Seldinger technique (**Figure 2, 3**). An 18-ga over-the-needle catheter is used to puncture the renal pelvis from the caudal pole of the kidney (if pelvis is > 8mm). If the pelvis is < 8mm, then a ureterostomy catheter is typically placed, so an area of fat is dissected off the caudolateral aspect of the kidney. This is expanded upon below; see below for placement of SUB *down the ureter in a small renal pelvis* (**Figure 4**). Once a flash of urine is obtained the needle is removed and the T-port with a 3-way stop-cock and 3 mL syringe (empty) with 3 mL syringe (50% contrast) is used for a pyelocentesis and pyelogram (**Figure 1,3**). With the empty syringe a urine sample is obtained for culture. The 50% diluted sterile iodinated contrast (iohexol) material is then injected into the renal pelvis to perform an antegrade pyelogram (**Figure 3A**). The ureter is monitored using fluoroscopy to document patency and obstruction location. Then, a 0.035" J-tip guide wire is advanced through the 18-ga catheter and coiled inside the renal pelvis being careful to avoid perforation of the renal pelvis or the ureter (**Figure 2,3**). This wire can be straightened using digital retraction of the wire, or using the introducer. Once the entire J-tip is within the renal pelvis (**Figure 3B**) the 18-ga. catheter is removed while the wire is carefully secured with a hemostat at the renal capsule to avoid losing wire access (**Figure 2C**). The 6.5F catheter, with the hollow cannula, is advanced over the guide wire into the renal parenchyma (**Figure 2D,E,F, 3D**). Once it enters the renal pelvis, the hollow cannula is retracted as the catheter is advanced over the guide wire creating a pigtail inside the renal pelvis (**Figure 3D-F**). Care is taken to ensure the black radiopaque marker is inside the renal pelvis as that marks the last fenestration of the catheter, which should always be within the renal pelvis (**Figure 3E,F**). This can be very tight, so be sure to pin the wire and catheter as the cannula is withdrawn in a twisting motion, while manually holding onto the kidney. Gentle twisting of the cannula within the catheter as well as keeping the catheter flushed and moist helps facilitate sliding along one another. The locking string is then gently pulled to prevent catheter dislodgement. **Care should be taken to ensure it is not pulled too tight which can kink the pigtail within the pelvis.** The string is then clamped with a hemostat at the junction of the string and catheter to maintain tension (**Figure 6E**). Be sure not to clamp the catheter itself, but just the string at the junction of the catheter and the string. Keep the hollow cannula in the straight part of the catheter but not inside the pelvis by the loop (**Figure 3E**).

The Dacron cuff is then gently advanced down the nephrostomy catheter to the renal capsule to keep the catheter snug in the renal pelvis (Figure 2E,F). Using the hollow cannula, inject and drain contrast from the nephrostomy tube to ensure proper placement, filling and drainage (Figure 3E,F). Then, remove the hollow cannula and apply the sterile cyanoacrylate glue between the Dacron and the renal capsule, which aides to provide security and prevent leakage (Figure 2E,F).

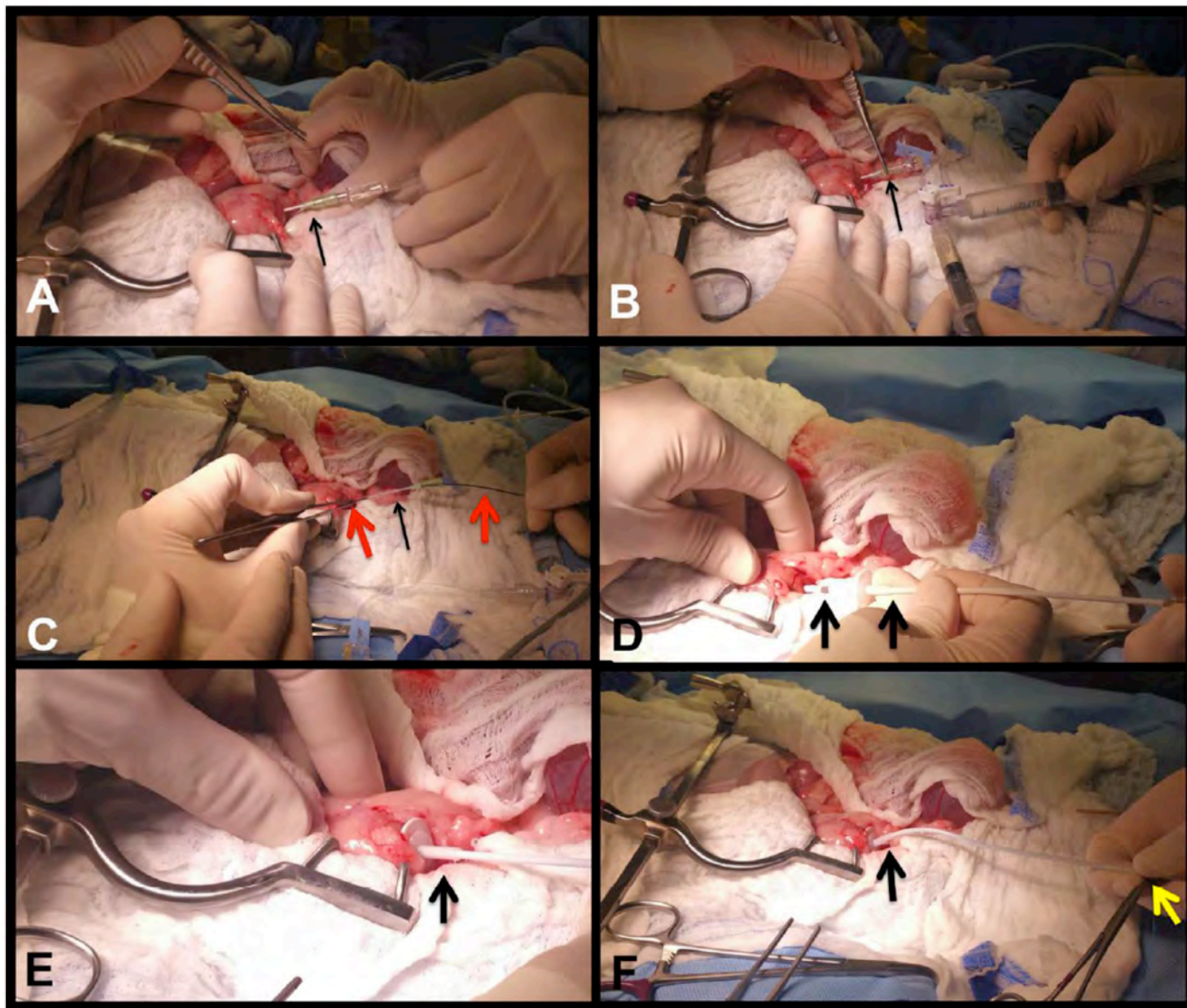


Figure 2: Nephrostomy access into the kidney

- A) 18G IV catheter (black arrow) puncturing the renal pelvis through the caudal pole of the right kidney after fat dissection.
- B) Urine draining from the IV catheter (black arrow) during pyelocentesis, which is followed by a pyelogram using contrast material on the stop-cock.
- C) 0.035" guidewire (red arrow) advanced into the catheter (black arrow) and coiled inside the renal pelvis, while the catheter is being removed over the guide wire.
- D) Locking-loop nephrostomy catheter (black arrows) advanced over the guide wire and into the renal pelvis.
- E) Nephrostomy catheter (black arrow) within the renal pelvis. The Dacron cuff and silicone sleeve are advanced to the level of the renal capsule.
- F) Nephrostomy catheter (black arrow) within the kidney. The string is locked using a hemostat at the end of the catheter (yellow arrow).

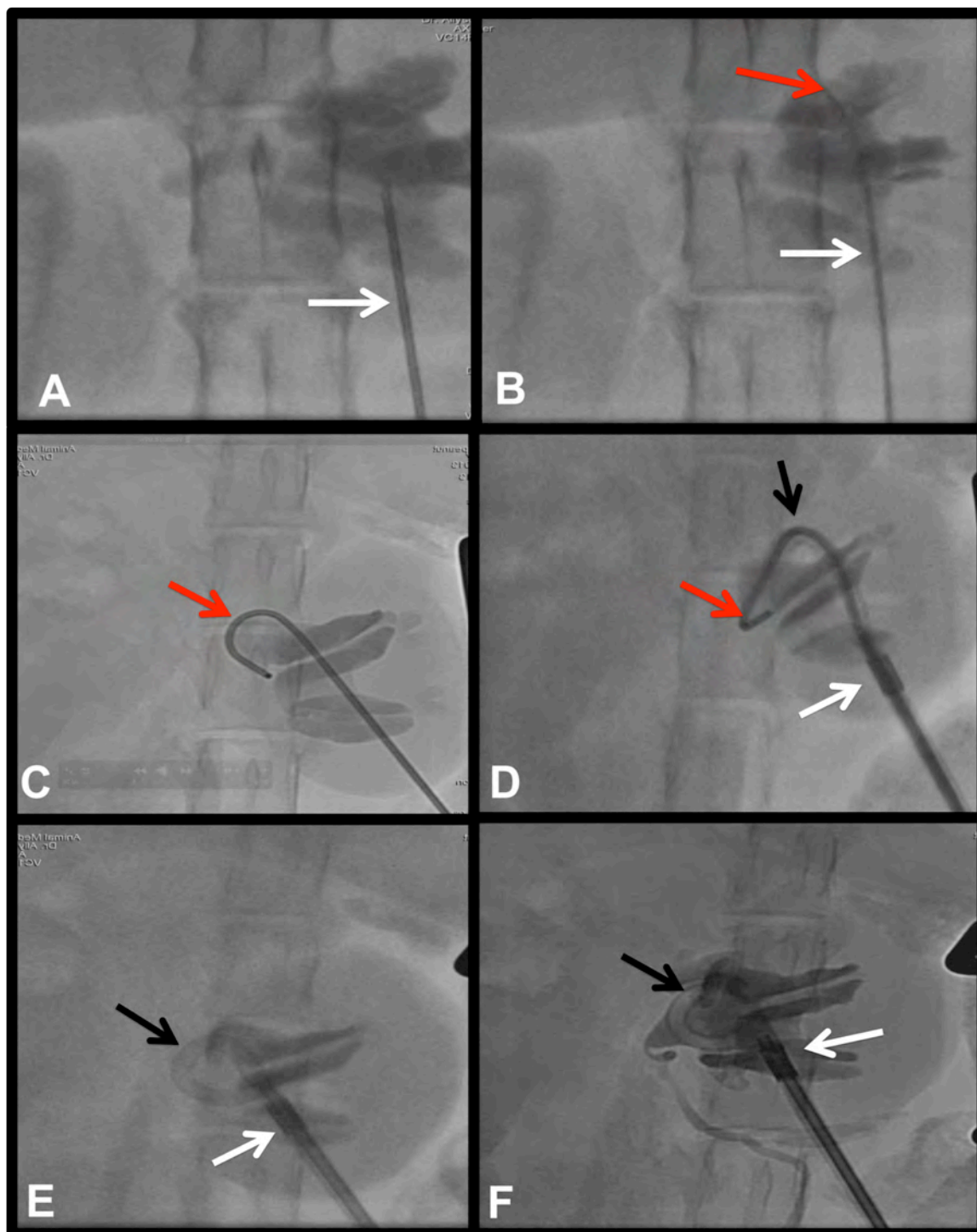


Figure 3: The Modified-Seldinger technique being used for locking loop nephrostomy access

- A) 18 ga IV catheter (white arrow) being placed into the caudal pole of the renal pelvis and a pyelogram being performed.
- B-C) A 0.035" J-tip guide wire (red arrow) advanced through the catheter and coiled inside the dilated renal pelvis.
- D) The locking loop nephrostomy catheter (black arrow) is advanced over the guide wire and hollow cannula inside the renal pelvis allowing a curl to form over the wire (red arrow) within the renal pelvis. The white arrow is the radiopaque marker which marks the last hole of the multi-fenestrated loop, ensuring the entire loop is within the renal pelvis.
- E) Once the radiopaque mark is within the renal pelvis (white arrow), the wire and hollow trocar are removed, the string is locked.
- F) A pyelogram is performed to confirm no leakage and appropriate catheter placement. Notice the pigtail catheter loop is tight and locked with the mark (white arrow) within the large dilated pelvis.

PLACING THE NEPHROSTOMY TUBE DOWN THE URETER FOR PELVISES < 5-8mm (Figure 4, 8D)

When a renal pelvis is smaller than ~8 mm, the authors' have found it easier and safer to place the nephrostomy catheter down the ureter instead of coiling it in the renal pelvis (Figure 4). This needs to be done very carefully using fluoroscopic guidance. The nephrostomy catheter is prepared by cutting the locking string at the loop and removing it from the hub of the catheter. We do not want to lock a loop down the ureter, so this is now more of a straight ureterostomy catheter that takes the curve of the proximal ureter.

Instead of puncturing from the caudal pole initially, we dissect the fat off of the caudal lateral aspect of the kidney to expose the renal capsule. Then, using a 22G IV catheter (Figure 4A), the renal pelvis is punctured from this region, aiming toward the ureter. Once a flash of urine is obtained, then a ureteropyelogram is performed. Then, using a 0.018" angle-tipped hydrophilic guide wire (*not included in SUB kit*), through the 22-ga catheter, the ureter is cannulated (Figure 4B). The wire is left down the ureter and the 22G Catheter is removed over-the-wire. Next, an 18G catheter is advanced over the guide wire (without the needle), and down the ureter (Figure 4C). The 0.018" guide wire is then removed and a 0.035" angle-tipped hydrophilic guide wire (*not included in SUB kit*) is advanced through the 18G catheter and down the ureter (Figure 4D). The 18G IV catheter is then removed over-the-wire, being careful not to remove the wire, and the nephrostomy catheter is advanced over the wire (Figure 4E,F), down the ureter, being passed off the hollow cannula, as described above. Once the catheter is in the ureter and the black mark is within the pelvis, then the Dacron cuff is advanced to the renal capsule and the silicone sleeve follows. The Dacron is then glued to the renal capsule as described above.

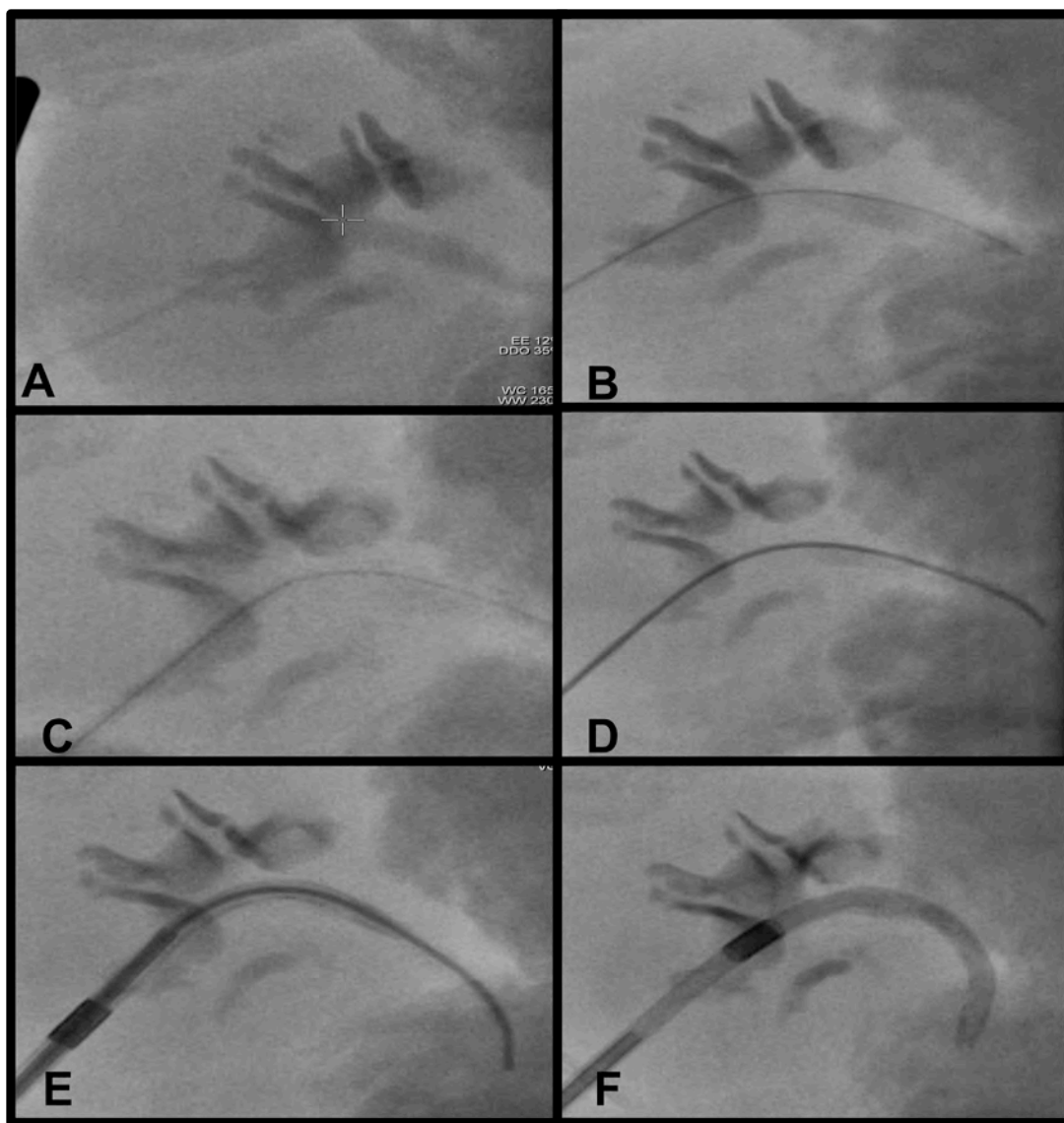


Figure 4: Placing the nephrostomy catheter down the ureter

A) Pyelogram of a renal pelvis with a ureteral obstruction using a 22G IV catheter.

B) 0.018" angle-tipped hydrophilic guide wire going down the right ureter.

C) 22G catheter removed and replaced with an 18G IV catheter over the 0.018" guide wire.

D) A 0.035" guide wire is advanced through the 18-ga IV catheter.

E) Nephrostomy catheter is advanced over the guide wire down the proximal ureter.

F) The black marker band is noted to be well within the renal pelvis during a pyelogram.

PLACING THE CYSTOSTOMY CATHETER

The urinary bladder catheter is now placed (Figure 5). First, using 3-0 monocryl in a purse string suture pattern is made at the apex of the bladder (Figure 5A). If there will be bilateral SUBs implanted, then each catheter should be placed just off midline so both fit as close to the apex as possible. In the center of this purse string, a #11 blade is used to puncture a small hole into the bladder lumen (Figure 5B) making sure to pierce the bladder mucosa. The locking-loop catheter is then prepared with the hollow cannula in the center. The string is pulled so there is no excess. The Dacron cuff and silicone sleeve are pushed down about 5 mm from the end of the black mark toward the loop so that there is no excess catheter in the urinary bladder. Next, the straightened locking-loop cystostomy catheter, with the hollow cannula in place, is advanced through the incision and into the urinary bladder lumen (Figure 5D) to the level of the Dacron cuff. The catheter is advanced off the cannula so that the pigtail is formed and the string is pulled and locked in place, as described above for the kidney catheter. The catheter is advanced until the Dacron cuff is against the serosal surface of the bladder, and the purse-string suture is secured and tied. Using 3-0 monocryl suture, the Dacron cuff is sutured to the bladder wall (full thickness) using 3 or 4 sutures (Figure 5E). Notice how the suture is passed through both the superficial silicone ring and the deeper Dacron disc (Figure 5E). Sterile cyanoacrylate glue is used to further secure the Dacron to the serosal surface of the urinary bladder (Figure 5F), and this can be done before or after suturing the catheter. **There is a radiopaque marker on the bladder catheter identifying the last hole to ensure that the entire catheter is within the bladder lumen. Care should be taken to ensure that this catheter is not too far into the bladder as this could be irritating. If the bladder is small, the pigtail should be pulled back even more and the Dacron and silicone sleeve can be adjusted.** Also, care should be taken to ensure the locking loop is not too tight to be kinked or too loose to be taking up extra space in the bladder. Fluoroscopy is very helpful here. Once secure, saline is infused through the hollow cannula and the seal is leak tested. Once satisfied with no leak, the hollow cannula is removed.

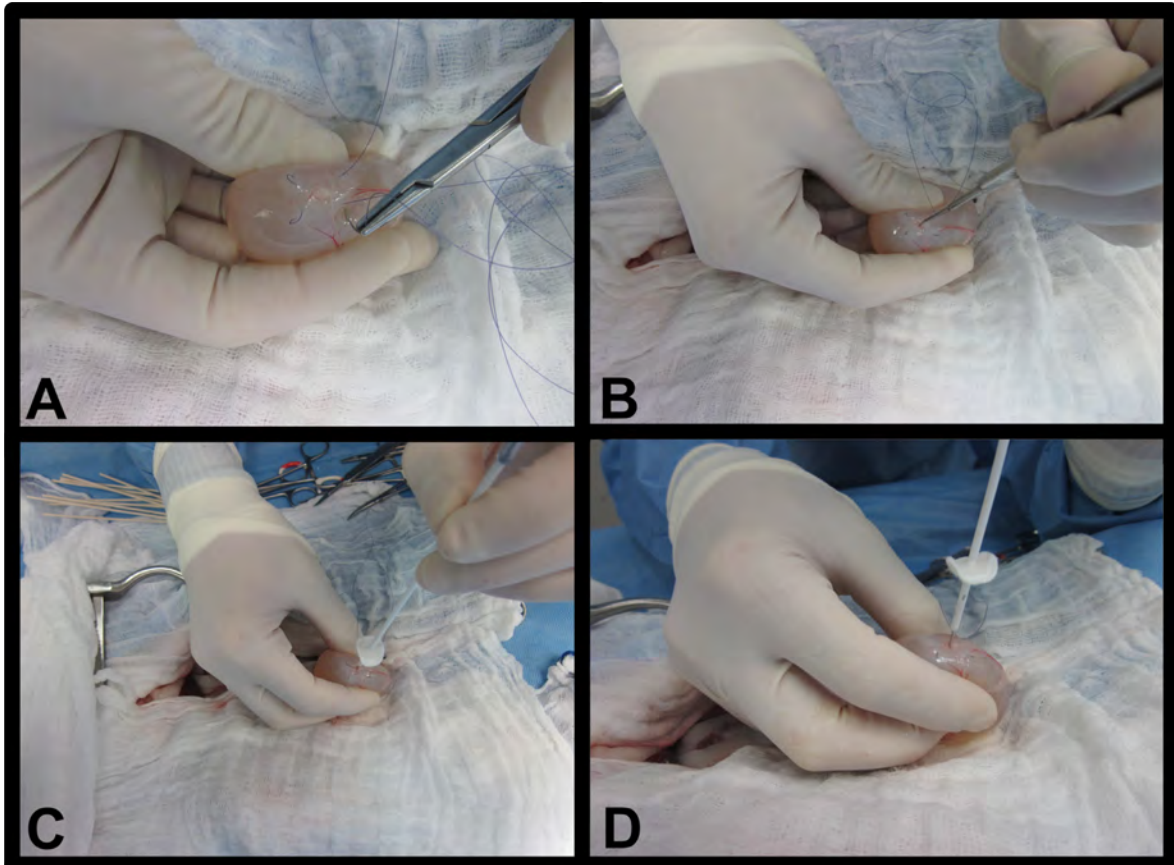


Figure 5 A-D (E-F on next page): Placing the cystostomy catheter

- A) A purse string suture is made at the apex of the bladder.
- B) A #11 blade is used to make a stab incision in the center of the purse string.
- C-D) The bladder catheter is advanced through the stab incision with the hollow trocar and sharp stylet in place. Then the purse string is secured around the catheter and tied.

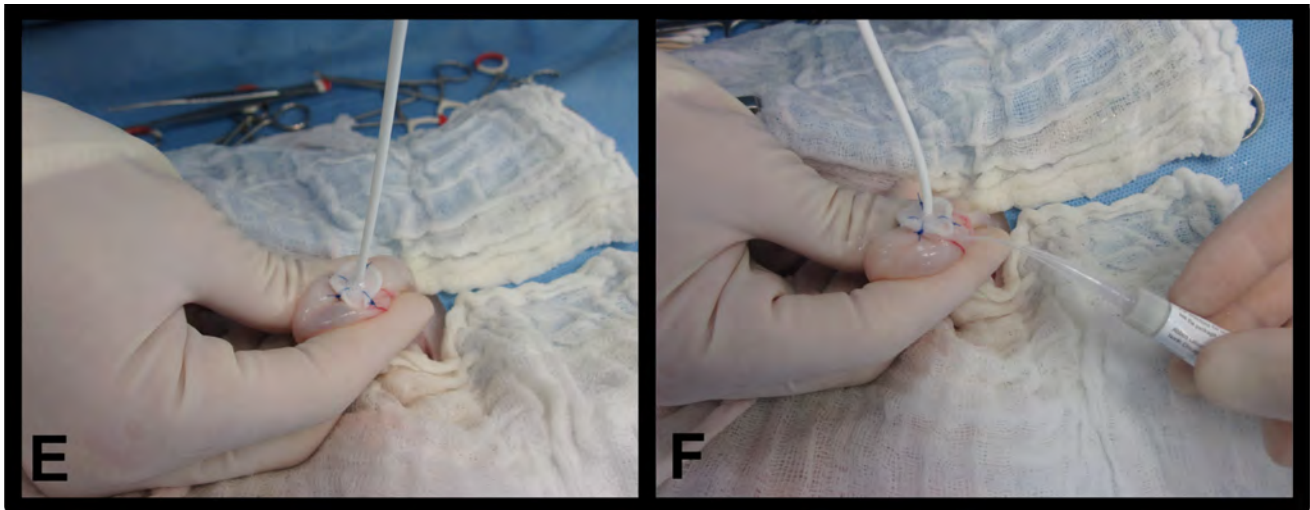


Figure 5 E-F: Placing the cystostomy catheter (continued)

- E) The silicone/Dacron cuff is sutured in 1 spot.
- F) Tissue glue is applied to the Dacron cuff adhering to the serosal surface of the bladder and an additional 2 or 3 sutures are placed to secure the catheter to the bladder wall.

PLACING THE CATHETERS THROUGH THE BODY WALL

Finally, the skin and subcutaneous tissues immediately lateral to the ventral abdominal incision on the ipsilateral side of the nephrostomy tube is dissected down to the abdominal musculature (**Figure 6A**). Both catheters are passed gently through the body wall (**Figure 6D**). The location where these catheters penetrate the body wall is very important. Lay the port over the body wall as seen in **Figure 6B**. This should be approximately halfway between the xiphoid and the pubis. The proximal hole created should be approximately 10cm from the distal hole. A sterile ruler could be used to accurately measure this distance. A cautery tattoo can be used to mark the spot on the ventral wall. We find that approximately 2-3 fingers in front of the port and behind the port (**Figure 6C**) is equivalent to approximately 9cm in length.

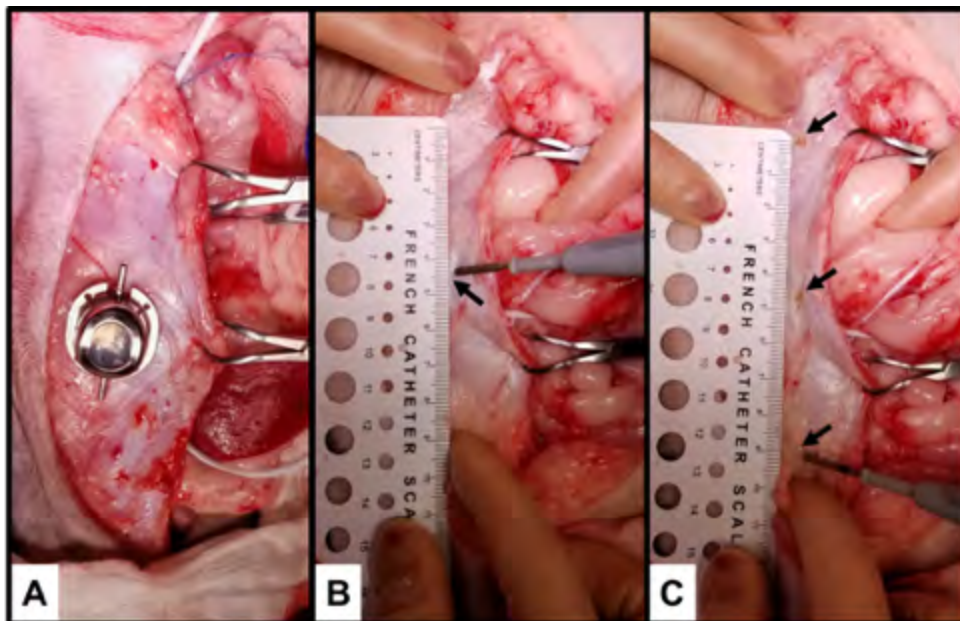


Figure 6 A-C (E-F on next page): Placing the catheters through the body wall

- A) The ventral abdominal fat is gently dissected off the body wall from the incision laterally on the ipsilateral side of the obstructed kidney. The port is laid on the body wall approximately halfway between the xiphoid and the pubis.
- B) The center of the port is marked (black arrow) with cautery.
- C) The location for catheter penetration through the body wall is chosen 4.5cm cranially and caudally to the central mark (black arrows). These should be approximately 9cm apart, with the port in the middle.

A hemostat is then used to penetrate the ventral body wall (**Figure 6D**). Typically, the nephrostomy catheter is attached to the caudal aspect of the port and the cystostomy catheter is attached to the cranial aspect, which maintains a gentle bend to the port and helps to prevent kinks (**Figure 8**). Using blunt dissection with a mosquito hemostat, a puncture is made through the body wall and into the abdomen (**Figure 6D**), and the mouth is expanded to open the hole to prevent it from being too tight. The ends of the hemostat carefully clamp the locking string at the end of the catheter, and the string and catheter are pulled through the body wall in unison (**Figure 6D**). **Do Not Clamp The Catheter Itself.** Once the catheter is through the body wall the string is kept locked and the blue cuff is placed over the end of the catheter (tapered end first) (**Figure 6E,F**) while holding the string tight manually to maintain the lock. Fluoroscopy is used here to ensure the pigtail is not too loose or too tight prior to securing the lock onto the barbs.

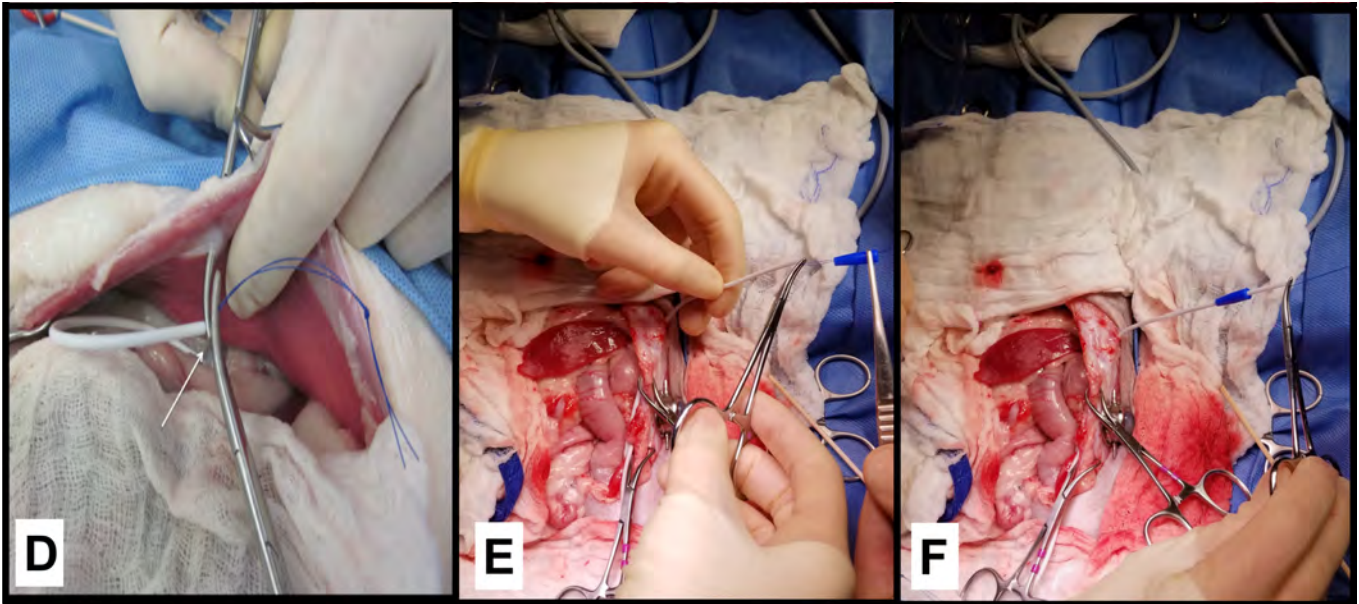


Figure 6 D-F: Placing the catheters through the body wall (continued)

D) Using small hemostats, a stab incision is bluntly made through the body wall and into the abdomen and the string of the catheter is secured.

E-F) The string and catheter are pulled through the rectus muscle maintaining the locking string, and the blue boot is placed over the string (tapered side first) and onto the catheter.

Then, the barb of the shunting port is advanced onto the catheter (**Figure 7**). Once the first rung of the barb is within the catheter, the string will be wedged between the barb and the catheter, which will lock the string. A #11 blade is then used to cut the string flush with the catheter end, against the metal barb (**Figure 7A,B,E**), being careful to avoid having any excessive string out of the catheter, as this can be a site of leakage. Then, the catheter is advanced over all of the barbs so that it is snug (**Figure 7C,D**).

The string should not be hanging out of the end of the catheter once it is advanced onto the port. This makes an incomplete seal and a site that can leak.

The pre-loaded blue cuff is advanced over the catheter to the port (**Figure 7D**). The same technique is then done for the other catheter (**Figure 7E,F**).

If there is a ureterostomy catheter, then there is no string to cut, so the catheter is simply advanced onto the port with the blue boot preloaded once it is through the body wall, as described above. To pull this catheter through the body wall, the tip is clamped with a hemostat. Since the end of the catheter could get damaged, the tip of the catheter is then cut with scissors and the end is discarded. The blue boot is advanced over the catheter, ensuring the tapered end goes down the catheter and the thicker blunt end is towards the shunting port. Finally, the shunting port is attached to the catheter for a secure connection. Care should be taken to ensure there is enough space made for the shunting port with both arms and the blue cuffs. Leaving approximately 1 cm of catheter between the end of the blue boot and the entry to the abdomen encourages a gentle bend into the abdomen so the catheter does not kink (**Figure 7F**).

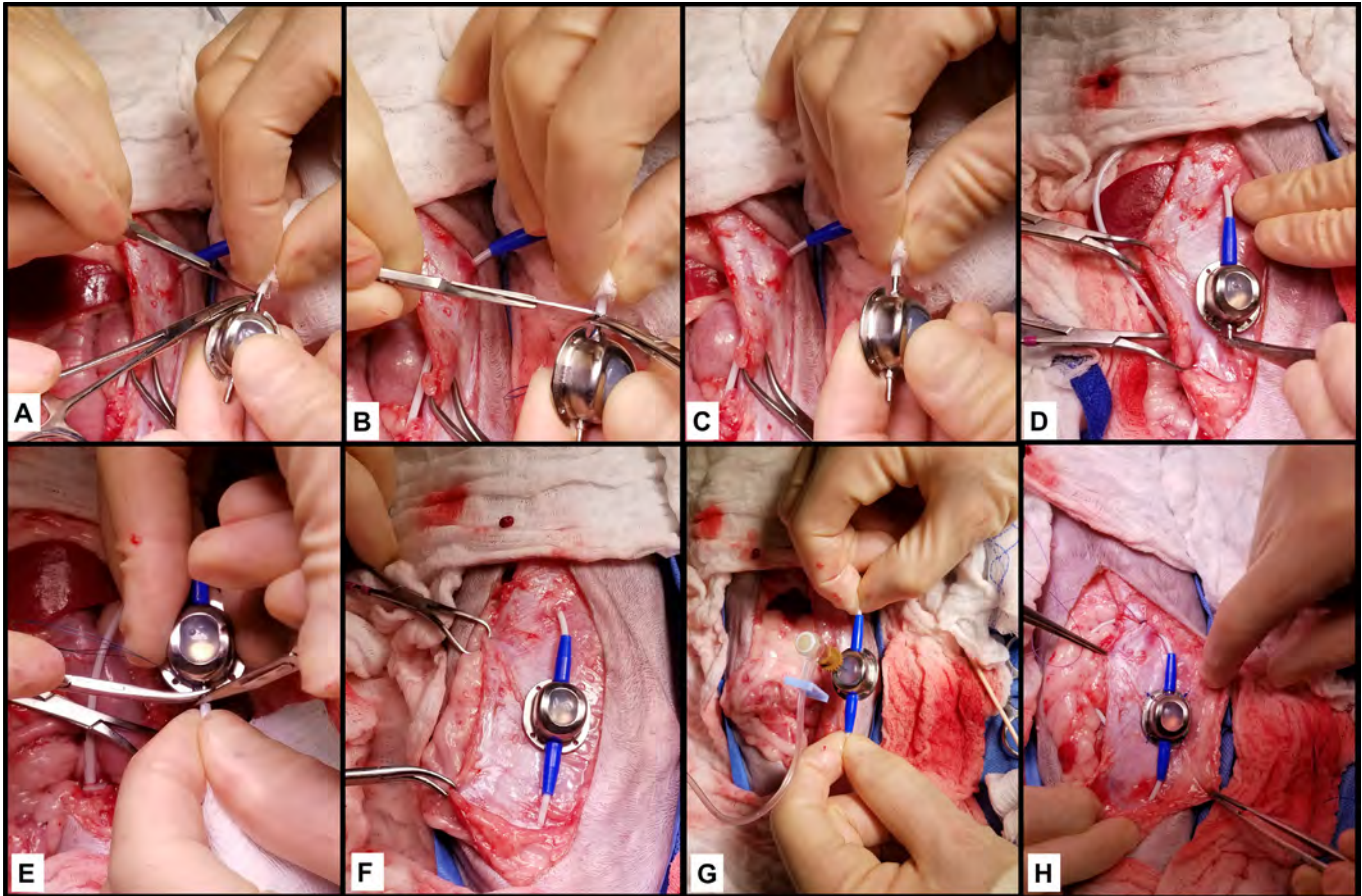


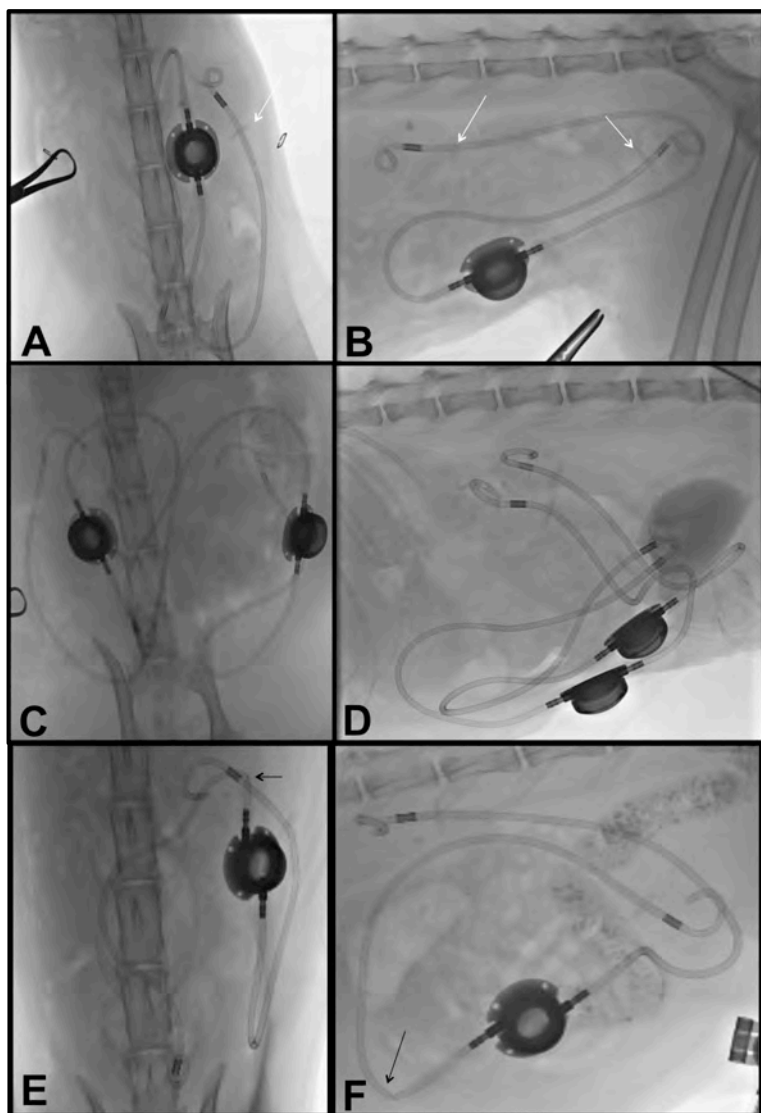
Figure 7: Detailed steps on securing the catheters to the shunting port

- A) The string is wedged between the first rung of the barb on the shunting port and the catheter to maintain the lock.
- B) A #11 blade is used to cut the string flush with the end of the catheter. No excess string should be present.
- C-D) The catheter is advanced over the barbs. The blue boot is advanced over the catheter and barbs.
- E) Steps A through D are repeated for the other catheter.
- F) The port is assessed to ensure there is enough space at the entry through the body wall (white catheter and blue boot should be visualized.)
- G) The port is leak tested to ensure no leaks.
- H) The port is sutured to the body wall with non-absorbable suture material.

As mentioned above, the bladder catheter is secured to the cranial barb of the shunting port and the kidney catheter to the caudal barb (Figure 8). This too prevents kinking by making a nice gentle loop within the abdomen prior to passing through the body wall. The excess catheter should remain in the abdomen. If there is excessive catheter resulting in kinking of the tubing in the abdomen, or at the entry into the SQ, then the catheters might need to be cut shorter. When this is done, you should preserve the locking-string, especially for the bladder catheter. Excessive catheter within the bladder lumen, if either advanced in too far, or the loop is not locked tight enough increases the catheter footprint, which could result in dysuria.

Once the system is closed, it is **leak tested**. Both kidney and bladder catheters are digitally compressed (Figure 7G) and a Huber needle is used to infuse saline into the system and ensure there is no leak at the junction of the port and the blue boot. If any string is hanging out, then this could leak and must be fixed immediately.

Once leak tested, the port is sutured to the ventral body wall (using non-absorbable synthetic 3-0) through the ventral rectus sheath to each of the 4 eyelets of the port to secure it in place (Figure 7H). Ensure the port is halfway between the xiphoid and the pubis, and ensure each hole entering the abdomen is approximately 10cm apart and even on each side of the port (Figure 7F,H).



Next, using digital subtraction angiography (DSA), a 50% mixture of contrast and saline is used to flush the entire system under fluoroscopic guidance. Care should be taken to monitor that the renal pelvis and bladder fill and drain easily.

The catheters need to be examined carefully at the renal capsule entry point, apex of the bladder entry point, and both sides of the shunting port for any leakage. In addition, all catheters should be examined for any kinks (Figure 8).

The subcutaneous pocket is closed routinely and any dead space addressed. Topical bupivacaine is placed in the SQ pocket around the port to provide additional analgesia. Once complete, a fluoroscopy image is taken in both VD and lateral to ensure no kinks are seen and the catheter is well situated in the renal pelvis and urinary bladder (Figure 8). The radiopaque marker on the nephrostomy catheter should always be within the renal pelvis and the Dacron cuff can be seen at the margin of the caudal pole of the kidney.

Figure 8: Ventrodorsal (A,C,E) and lateral (B,D,F) fluoroscopic images after SUB placement showing the kidney catheter attached to the caudal part of the port and the bladder catheter on the cranial part of the port. Note the radiopaque marker is well with the renal pelvis and bladder lumen and the Dacron cuff is seen along the caudal border of the kidney and bladder wall (white arrow). Kinks are noted in images E,F.

FLUSHING OF THE SUB (FIGURES 9, 10)

The details of performing a SUB flush and the follow-up recommendations are outlined in the SUB flush kit instructions for use manual (IFUs). Current recommendations include flushing the device prior to discharge, at 1-week post-operatively, then at 1-month, and every 3-months thereafter. During the flushing procedures, a urine sample is obtained for analysis and culture every 3 months, followed by infusion of a novel solution called tetrasodium ethylenediaminetetraacetic acid (tetra-EDTA), or *T-FloLoc™*. This substance helps prevent occlusion with stone material and biofilm formation. It can also be used to clear partially mineralized device and clear recurrent infections associated with biofilm, in the authors' experience with this material. This procedure typically does not require any sedation or anesthesia, is performed in dorsal recumbency using ultrasound guidance with minimal restraint, and can be performed more regularly in patients at higher risk for encrustation (e.g. hypercalcemic, history of device mineralization) or infection (e.g. pre-operative infection).

The SUB Flush Kit has been designed to include everything you will need to perform this procedure. The pack is sterile and the contents should be assembled using sterile gloves as depicted in Figure 9. The patient is positioned in dorsal recumbency in a V-trough to facilitate port access and ultrasonography. The following materials are included:

- | | |
|--|---|
| 1) 1 x T-port Connector | 4) 1 x 3mL Syringe (empty) |
| 2) 1 x 3-Way Stopcock | 5) 1 x 3mL Syringe w/2.5mL Sterile Saline |
| 3) 1 x 22 or 20 Gauge Huber Point Needle | 6) 1 x 12mL Syringe w/2mL T-FloLoc™ |

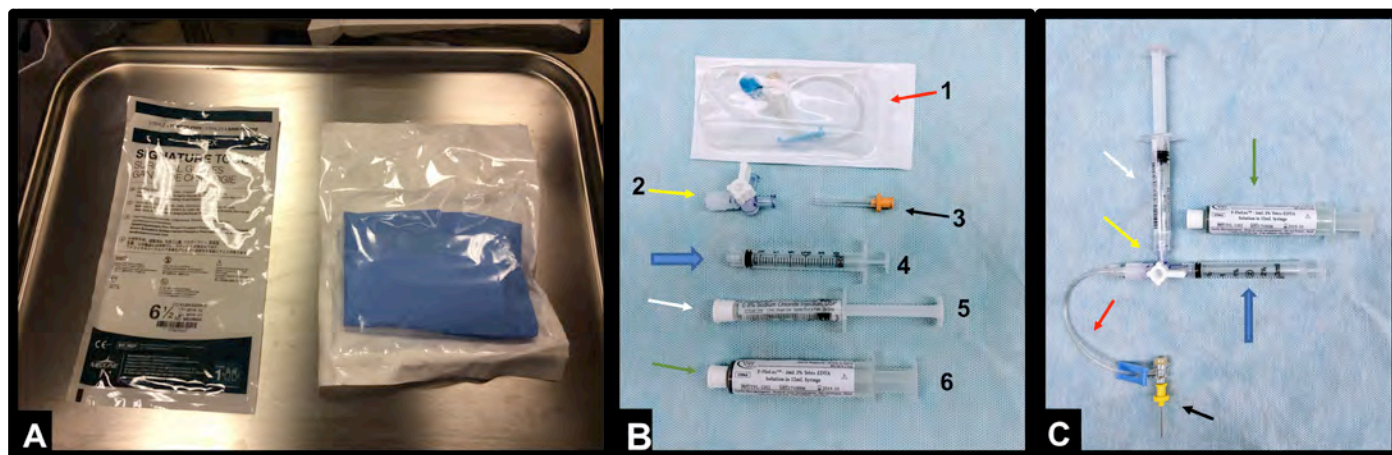


Figure 9: Set-up of the SUB Flush Kit

A) Sterile gloves and the flush kit.

B) The parts in the SUB flush kit. 1) T-port connector; 2) 3-way stopcock; 3) 22/20G Huber needle; 4) empty 3mL syringe; 5) 2.5mL sterile saline; 6) 2 mL of Tetra-EDTA (T-FloLoc™).

C) All of the parts attached properly to the system for flushing.

In addition you will need a clipper to clip the fur over the SUB port and scrub solution to adequately scrub the skin over the SUB port so that the procedure is done in a sterile manner (**Figure 10**). Prior to flushing, the renal pelvis sizes should be measured and recorded using ultrasound guidance, and the urinary bladder should be examined for bladder stones, or any thickened tissue around the SUB catheter (**Figure 10C**).

ULTRASOUND-GUIDED FLUSHING OF THE SUB (FIGURES 10, 11)

This should be done through the shunting port using a Huber needle (**Figure 9B,C; Figure 10**). An extension set with a 3-way stopcock is used with one empty syringe for urine sampling and one syringe filled with sterile saline (ultrasound-guidance). The shunting port is palpated under the skin and the silicone insertion site is isolated (**Figure 10A**). Using sterile technique, the Huber needle is advanced through the skin, into the silicone diaphragm until metal is reached. This must be done in a perpendicular manner (**Figure 10A**).

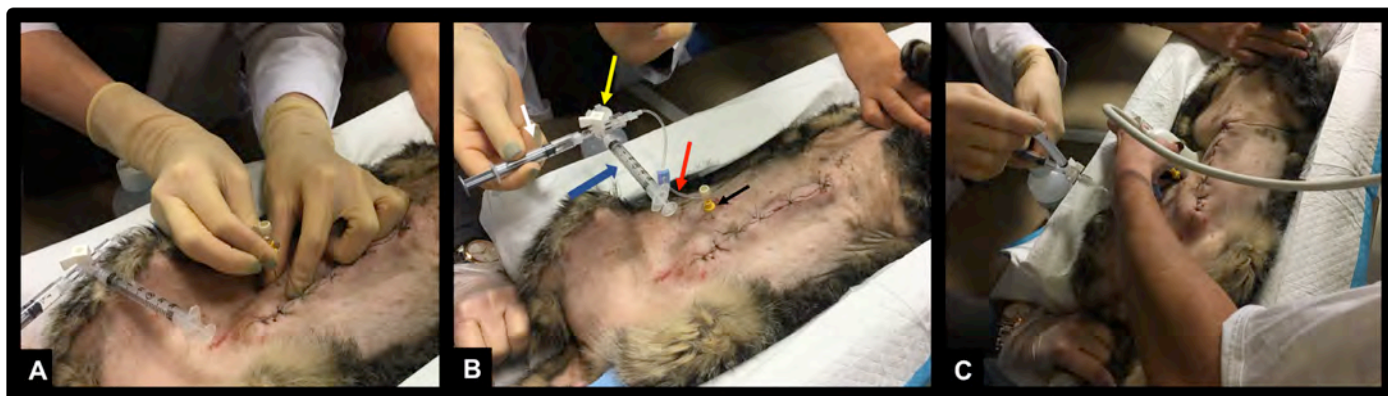

Figure 10 A-C (D-F on next page):

The cat is placed in dorsal recumbency and the port site is clipped and aseptically prepared and scrubbed using chlorohexidine surgical scrub.

A) The Huber needle is inserted into the port using sterile technique and sterile gloves. Once metal is hit with the needle (black arrow) and the needle is within the well than the system is in place.

B) The empty syringe (blue arrow), 3-way stopcock (yellow arrow), T-port (red arrow), and sterile saline (white arrow).

C) Ultrasound is used to evaluate the renal pelvis and urinary bladder measuring size and evaluating for any pathology.

Once the needle is inside the shunting port, a urine sample is obtained (Figure 10E). If no urine is withdrawn, then the needle is either not deep enough into the access port, at the wrong angle, or the system is occluded on both ends. Once urine is obtained (and submitted for urine culture and urinalysis) the sterile saline is carefully injected into the port while the renal pelvis is being monitored with ultrasound guidance (Figure 10F, Figure 11). Once saline is seen to enter the renal pelvis (usually confirmed by the presence of small air bubbles (Figure 11A), the fluid is withdrawn to avoid over-distension. Next, the ultrasound probe should be placed over the bladder apex and the port should be flushed again using the SAME VOLUME of saline to see fluid enter the urinary bladder through the SUB cystostomy tube (Figure 10F, 11B). Again, bubbles are usually seen (Figure 11B).

Care must be taken NOT to overfill the renal pelvis during monitoring of the urinary bladder. The renal pelvis should ALWAYS be monitored during this procedure with ultrasound (or fluoroscopy) to ensure it is not being over-distended.

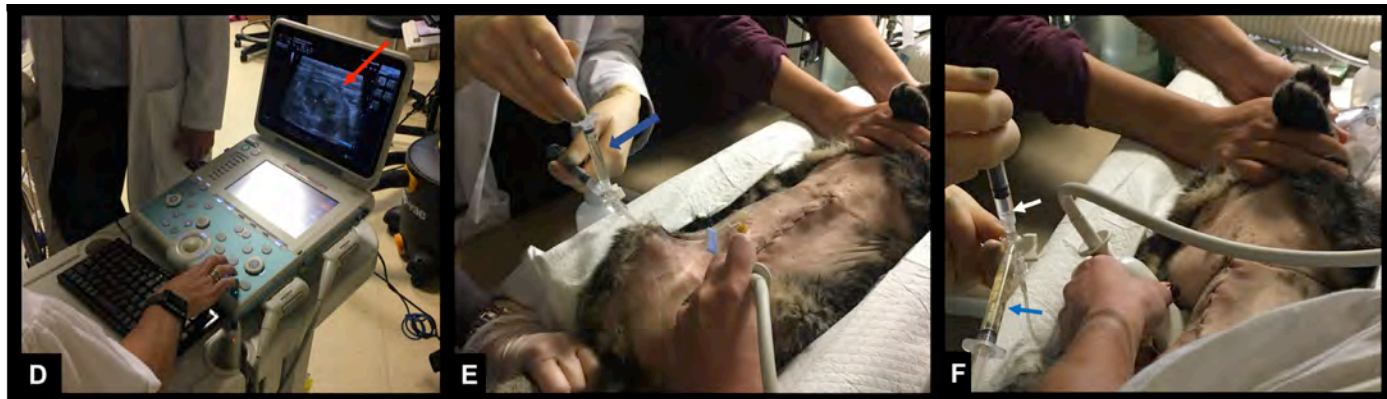

Figure 10 D-F: The flushing procedure (continued)

D) Ultrasound image of the kidney with the SUB coming through the caudal pole (red arrow).

E) Urine being drained from the port (blue arrow).

F) saline being infused into the system (white arrow), monitoring the kidney with ultrasound guidance.

Once patency is confirmed, then the urine sample is removed from the 3-way stopcock and the syringe with T-FloLoc is attached to the system. Monitoring of the renal pelvis using ultrasound guidance is necessary. Once the renal pelvis is drained empty, the flush solution is slowly flushed into the renal pelvis avoiding any over-distension. This is done in pulses to allow for the solution to drain down the sub between each pulse. Typically, 1-2 mL is infused if no distension is seen. If the renal pelvis shows any distension, then stop the infusion until it resolves. If it does not resolve in a few seconds, then discontinue the flushing. This technique is only for prophylactic flushing. If the T-FloLoc solution is being used for treatment of mineralization or biofilm, please follow the appropriate protocol, which is available through Norfolk Vet. Once the flush is complete, the needle should be removed from the port carefully, and the procedure is complete.

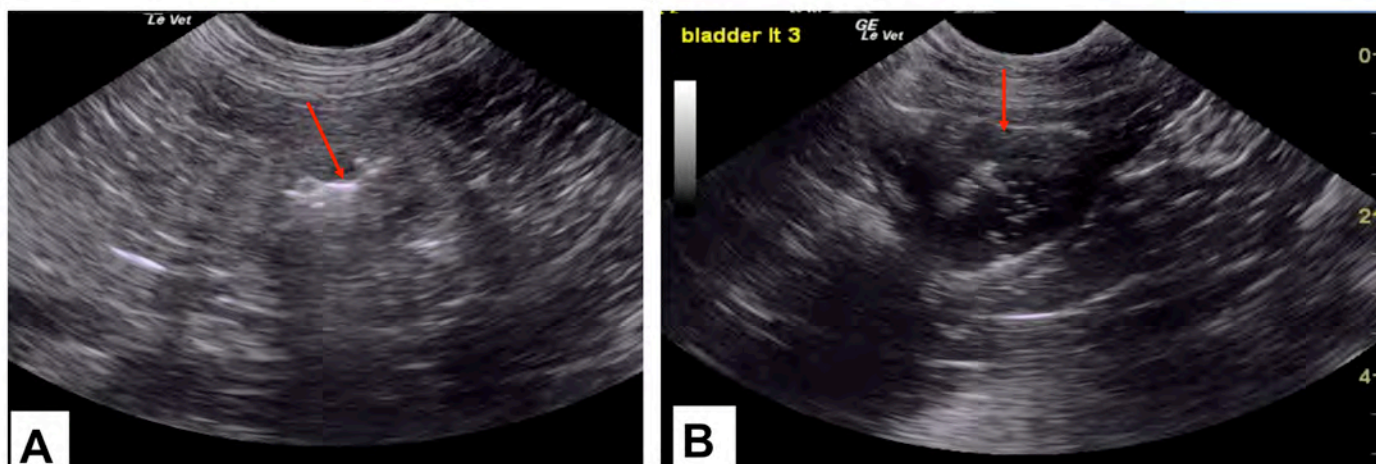


Figure 11: Ultrasound images of the kidney (A) and the Bladder (B) during an infusion. Note the bubbles (red arrows)

FLUOROSCOPIC-GUIDED FLUSHING OF THE SUB (FIGURE 12)

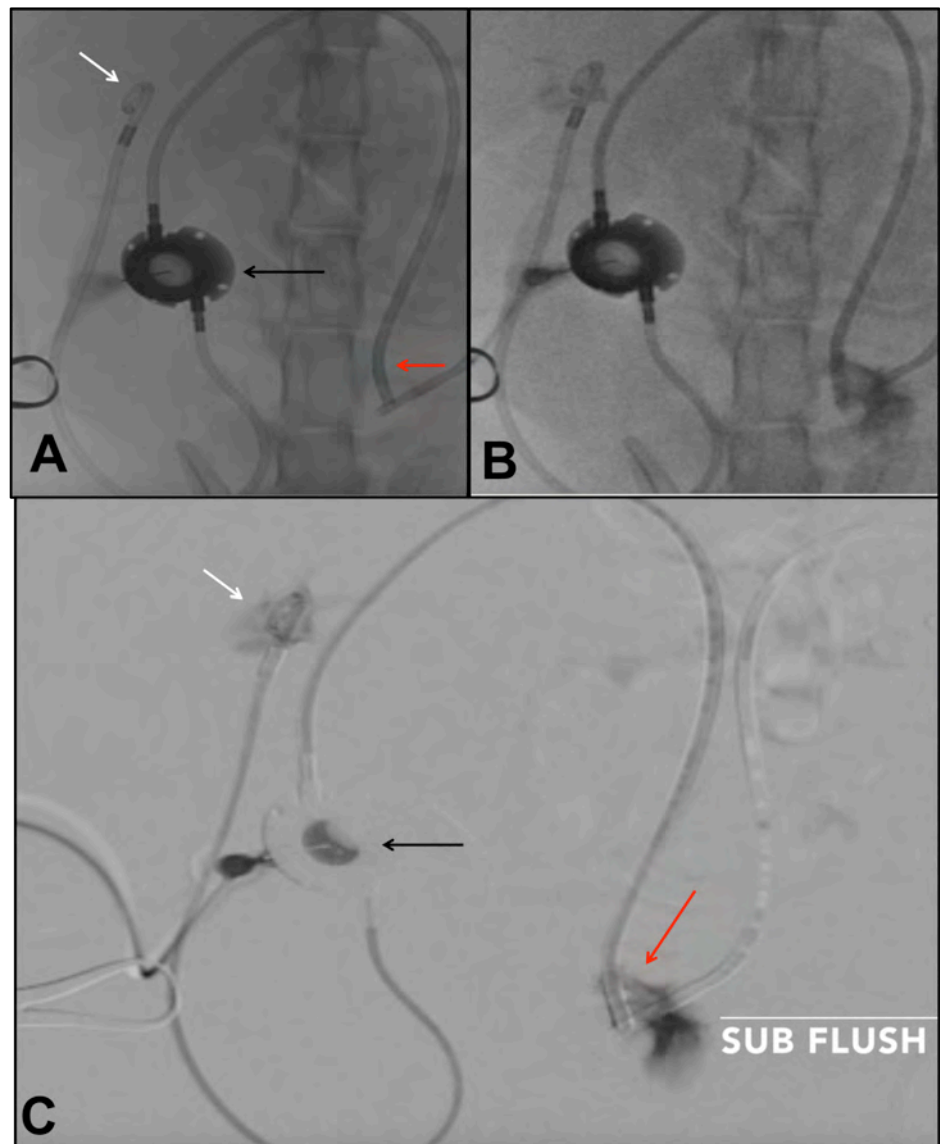This technique is uncommonly used for routine SUB flushing, but can be useful for cases in which ultrasound-guided flushing is insufficient, unavailable or inconclusive. If the flush is being done under *fluoroscopic guidance*, then you need 100% of iohexol (240-360mg/mL) in a 3mL syringe connected to the T-port, 3-way stopcock, and empty syringe system (Figure 9). Ultrasound is not needed for the flush but should be used prior to the flush to get accurate renal pelvis size measurements to ensure proper function of the SUB device. The patient is placed under the fluoroscopic unit in dorsal recumbency, and the port area is clipped and scrubbed aseptically as described above. The fluoroscopy image should be aligned with the patient so that the kidney, port and bladder are seen in the image. After the urine sample is obtained, to ensure proper needle placement, the contrast solution is injected into the port. Careful monitoring of the contrast should be seen using fluoroscopy traveling from the port, up the catheter, to the kidney while the renal pelvis fills (Figure 12). This is ideally done using digital subtraction angiography (DSA), as long as the patient is not moving (Figure 12C). If the patient is not sedated, then DSA is more difficult, so regular fluoroscopy is used (Figure 12A,B). The pelvis should not be over-distended and the injection should be done slowly (0.5ml at a time after 3ml drainage). The renal pelvis and the urinary bladder should be monitored simultaneously (Figure 12B,C) to ensure both catheters are filling with contrast, and to ensure there is no renal pelvis over-distension. Then, all of the contrast should be easily withdrawn from the bladder and the renal pelvis. Then, the T-FloLoc™ syringe is mixed with 1mL of contrast. This mixture is attached to the stopcock, and it is infused into the system slowly, avoiding renal pelvis over-distension. This should be done in 0.5mL increments with pauses, allowing drainage of the material between each pulse to avoid over-distension. 1-2mL of total solution should be infused. The needle can then be removed from the port carefully, and the flush is complete.

Figure 12: Fluoroscopic images of a cat with bilateral SUBs in dorsal recumbency

A) Incomplete SUB system visualization with the nephrostomy tube (white arrow), port (black arrow) and bladder catheter (red arrow).

B) Contrast is infused into the system after urine is drained, showing contrast in the renal pelvis, catheters and urinary bladder confirming patency.

C) Flush done under digital subtraction radiography (DSA) showing how much easier it is to see the contrast in the system. This can only be done with sedation or anesthesia as it requires a pause in breathing and movement.



COMPLICATIONS AND PROGNOSIS (TABLE 1, FIGURE 8, FIGURE 13)

The SUB device is an alternative for the treatment of ureteral obstructions in dogs and cats, especially when traditional surgery either fails, is contraindicated, or has a high risk of re-obstruction.

Considering that over 85% of cats with a ureteral obstruction have concurrent nephroliths and the median number of stones per ureter was documented to be 4 in a recent study⁹, a majority of cases seem to benefit from this approach in the authors' practice.

The device should only be placed by those trained with the technique, as a higher complication rate than that reported is typically seen when proper training is not pursued. These cases are technically challenging and can become very complicated. The authors recommend all new users to consider a training course prior to use. The authors are available for consultation via the email(s) above, and a textbook chapter¹² is available to help walk through the procedure details prior to placing the first SUB in a live animal. The authors also recommend first practicing on a cadaver or using the *3D printed silicone model* that is available separately through Norfolk Vet Products.

The acute decompression success rates are high (>98%), but training is mandatory. In a recent report in the authors' practice¹, patency of the device was evident long-term, followed for a median of 827 days (range: 1-2397), with improvement in the creatinine concentrations from a median of 6.8 mg/dL to 2.6 mg/dL, prior to discharge. Complications reported in this large study are documented in **Table 1**.

Device *leakage* was only seen in the intra- or peri-operative period and was rare (2.3-3.5%). This was almost always associated with a technical error of not cutting the locking string close enough to the catheter.

Kinking of the device was evident in the short- or long-term in 4.6% of cases. This was almost always a technical error where the entry of the device through the body wall was not far enough from the end of the blue boot. This is why the 10cm rule (hole to hole) should always apply.

Post-operatively, occlusion of the device (median 3.5 days) was almost always associated with the development of a *blood clot*. This occurred in 8% of cases. Half of these cases were easily addressed with infusion of 1mL of tissue plasminogen activator (TPA) into the SUB port. The cases where this failed, an exchange of the catheter was required. This 2nd surgery prolonged hospitalization by 1-day.

Mineralization of the device was seen in 24.5% of cats in the long-term at a median of 463 days. Half of those cases developed a patent ureter and did not require a SUB catheter exchange. The other half did require an exchange, and their median hospitalization time was 2-days, with 100% survival to discharge. Since the start of prophylactic flushing using tetra-EDTA (T-FloLocTM), the rate of mineralization has declined to 4% and post-operative infections to 2%. More data will be available shortly on these statistics.

Dysuria, which is commonly seen in cats with double pigtail ureteral stents (38%)⁹, was seen in 6% of cats with a SUB device alone. Most of these cats had a history of dysuria prior to SUB placement, negating the device as a primary cause. Chronic urinary tract infections were documented in 8% of cats over the course of the study, with a majority of cats that had more than one (1) infection in the long-term also had an infection at the time of SUB placement.

Overall, the use of a SUB for feline and canine patients with a ureteral obstruction can be considered a functional option when other traditional therapies have failed or are contraindicated. This is a technique that is best performed using fluoroscopic guidance to help avoid major complications. Many of the complications seen are technical and can be avoided with proper training. The biggest long-term complications are mineralization and infections, both of which are showing more promise with the prophylactic use of tetra-EDTA (T-FloLocTM). Again, operators should be well versed in interventional techniques and devices, the possible complications, and appropriately trained in the use of this device before trying this in a clinical patient.

Complications	Intra-operative (induction to < 8 hours) (n=174 units; 145 episodes; 137 cats)	Peri-operative (8 hours to 1 week) (172 units; 143 episodes; 135 cats)	Short-term (>1 week to 30 days) (165 units; 136 episodes; 128 cats)	Long-term (>30 days) 159 renal units; 131 episodes; 124 cats)	Total
Leakage	4/174 (2.3%)	6/172 (3.5%)			
Kinking	3 /174 (1.7%)	1/172 (0.58%)		4/159 (2.5%)	8 (4.6%)
Blood clot in device	4 /174 (2.3%)	9/172 (5.2%)	4/165 (2.4%)	1 /159(0.6%)	4 intra-op/14 post-op (8%); 5.2% required an exchange
Mineralization of device			1/165 (0.6%)	39/159 (24.5%)	40 (24.2%); 12.7% required an exchange
Dysuria		4/143 (2.8%)		7/124 (5.6%)	11/133 (8.3%); 8/133 (6%) unassociated with UTI or stent
Worsening Azotemia		2 /143 (1.4%)			1.4%
Chronic UTI (>1 symptomatic infection)				10/122 (8%)	8%
Death	2/145 (1.4%)	7/143 (4.9%)	4/136 (2.9%)	15/124 (11%) *3 cats LTF day 45, 365, 940, respectively	6.2% peri-op <=7 days 2.9%: 8-30 days 6.8%: >30-90 days 2.5%: >90-180 days 2.3%: 1 year

TABLE I. COMPLICATIONS

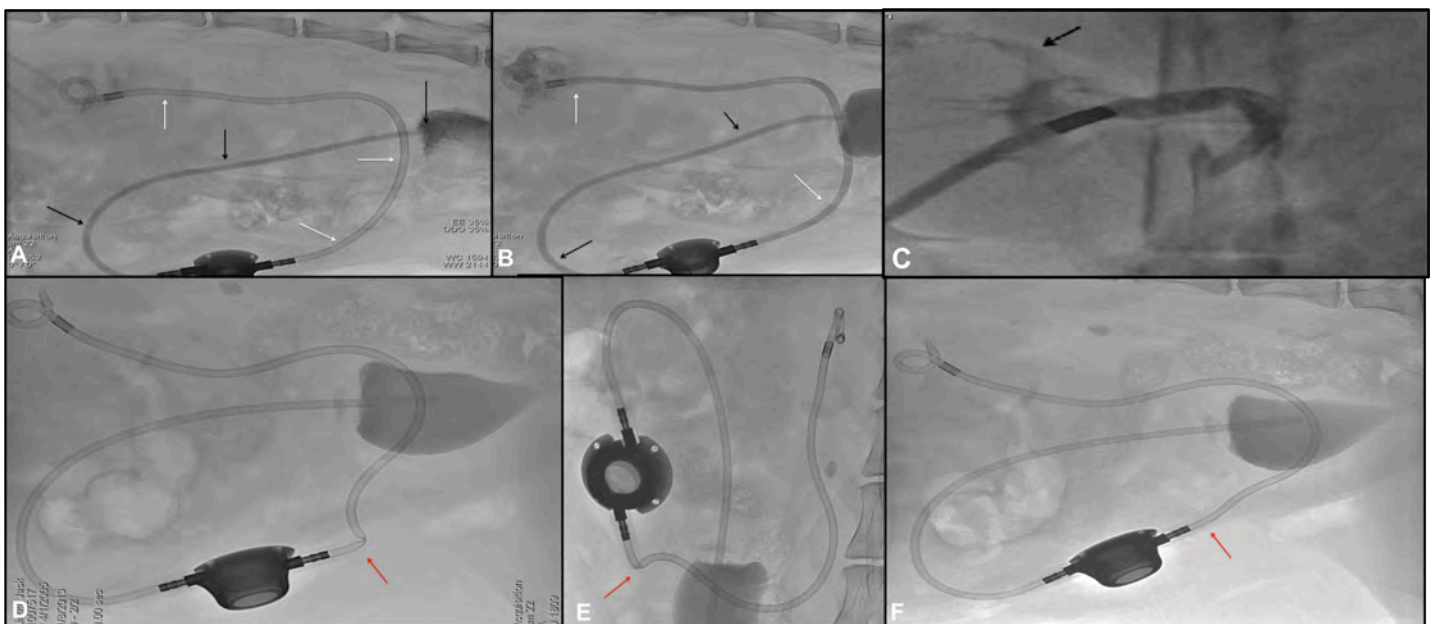


Figure 13: Fluoroscopic images showing some complications that can be seen with the SUB device

- A) Lateral image of a cat with a SUB device. During fluoroscopic flushing, at the end of the procedure, the cystostomy catheter (black arrows) is seen to fill with contrast but the nephrostomy tube (white arrows) is not filling. This was due to a severe pyonephrosis; with serial flushing the catheter eventually cleared and started flowing
- B) If this occurs, drain the entire system completely and then flush again, as it can be that the renal pelvis is too full to allow more flush.
- C) Leakage (black arrow) of contrast seen at the cranial pole of the kidney. This was due to inadvertent guide wire puncture of the renal calix which was of no clinical consequence.
- D-E) A kinked (red arrow) SUB device in a cat.
- F) After fixing the insertion hole of the catheter, the kink resolved.

MISCELLANEOUS

In addition to the traditional SUB™ device kit, there are 2 port sizes (small and large). The smaller port is ideal for very small, thin cats, but the larger SwirlPort™ is used in 99% of cats and dogs in the authors' practice. Additionally, there are 3 connectors that can be used: 1) the traditional port (small or Swirl); 2) a 3-way shunting port called The PantsPort™; and 3) an internalized metallic male-to-male barbed adaptor (Figure 14).

1) The traditional subcutaneous shunting port is most commonly used in animals for standard treatment of a ureteral obstruction. This gives access to the device for routine flushing and sampling. The smaller port was statistically more likely to occlude with mineral than the larger port over time, so this port is rarely used since 2015.

2) The 3-way PantsPort™ (Figure 14A) allows you to connect both kidneys to a single bladder catheter for bilateral ureteral obstructions. The authors prefer each kidney to have its own port when possible as flushing each side individually is ideal, but the PantsPort saves a fair amount of anesthesia time in compromised patients. This is typically reserved for patients being treated for obstructive neoplasia. The concern is that if the single bladder catheter becomes mineralized, it will block both kidneys. This is unlikely to occur in patients with neoplasia. The median time to occlusion was 463 days.

3) The internalized male-to-male barbed adaptor (Figure 14B) is used when the patient is not tolerating general anesthesia and the time it takes to secure the catheters subcutaneously is not possible (15-30 minutes additionally). This allows a fast connection to be made, with the same premise to lock the string and advance the blue cuffs, but there is no need to secure these connections to the body wall. It is left free within the abdomen. This does not allow flushing and sampling in the long-term, but in cases where kinks are continuously occurring at the body wall, this can help prevent such kinks.

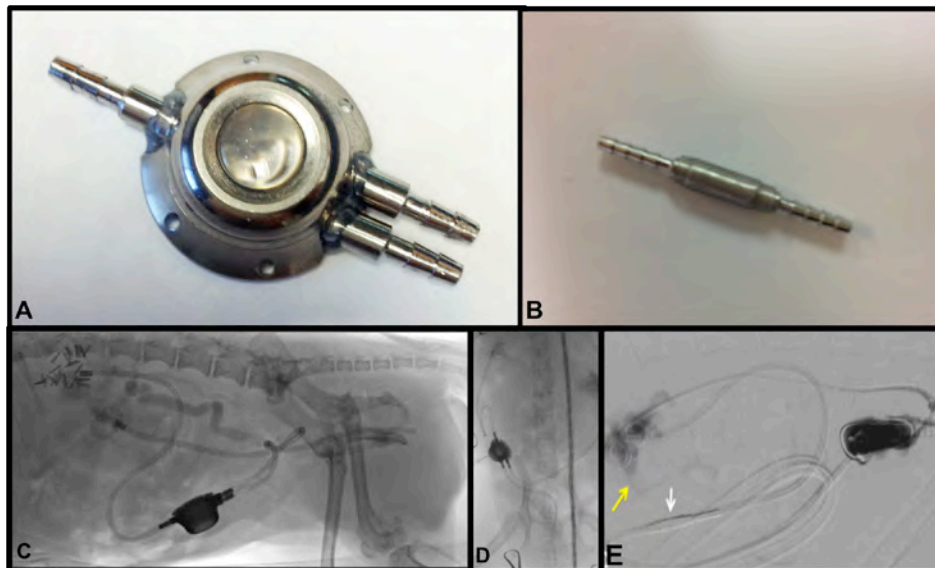


Figure 14: Miscellaneous equipment that can be used during ureteral bypass placement.

- A) This is a 3 way “PantsPort™” that can be used for bilateral ureteral obstructions where there are 2 kidney catheters and one bladder catheter that are all connected to one port.
- B) This is a male-male barbed adaptor that will connect the kidney to bladder catheter and remain internalized. This provides bypass without an access port so it is not subcutaneous. This allows for faster placement but does not allow the device to be serially flushed in the future.
- C) This is a lateral fluoroscopic image in a patient that had a “Pants-port” placed for obstructive neoplasia.
- D) AVD image of a dog with a “PantsPort”.
- E) Digital subtraction angiography (DSA) of a patient during a cystourethrogram where no SUB port was used and a male-to-male barbed adaptor was used (white arrow). Notice a leak of contrast from the renal pelvis (yellow arrow). This healed without intervention.

This section has been left blank for any notes you care to make:

REFERENCES

- 1) Berent A, Weisse C, Bagley D. et al. The use of a subcutaneous ureteral bypass (SUB) device for the treatment of benign ureteral obstructions in cats: 137 cats; 174 ureters (2009-2015). J Am Vet Med Assoc. in press, 2018.
- 2) Berent A. Ureteral obstructions in dogs and cats: a review of traditional and new interventional diagnostic and therapeutic options. J Vet Emerg Crit Care. 2011; 21(2): 86-103.
- 3) Steinhaus J, Berent A, Weisse C, et al. Clinical presentation and outcome of cats with circumcaval ureters associated with a ureteral obstruction. JVIM. 2015; 29(1): 63-70.
- 4) Horowitz, C, Berent A, Weisse C, Langston C, Bagley D, et al. Prognostic indicators of short and long-term outcome in cats with interventional management of ureteral obstructions. J Fel Med and Surg, 2013; 15(12): 1052-1062.
- 5) Azhar RA. 2010. Successful salvage of kidney allografts threatened by ureteral stricture using pyelovesical bypass. Am J of Transplant, 10:1414-1419.
- 6) Jurczok A. 2005. Subcutaneous nephrovesical and nephrocutaenous bypass-palliative approach o ureteral obstruction caused by pelvic malignancy. Gynecol Obstet Invest. 59:144-148.
- 7) Schmidbauer J. 2006. Nephrovesical subcutaneous ureteral bypass: long-term results in patient with advanced metastatic disease-improvement in renal function and quality of life. Europ Urol. 50: 1073-1078
- 8) Pavia P, Berent A, Weisse C, et al. Outcome following ureteral stent placement for benign ureteral obstructions in 44 dogs: (2010-2013) J Am Vet Med Assoc. in press March 2018.
- 9) Berent A, Weisse C, Bagley D, et al. Technical and clinical outcomes of ureteral stenting in cats for the treatment of benign ureteral obstruction: 2006-2010. J Am Vet Med Assoc. 2014; 244(5): 559-576.
- 10) Kyles A, Hardie E, Wooden E, et al: Management and outcome of cats with ureteral calculi: 153 cases (1984–2002). J Am Vet Med Assoc. 2005; 226(6): 937-944.
- 11) Culp W, Palm C, Hsueh C, et al. Outcome in cats with benign ureteral obstructions treated by means of ureteral stenting versus ureterotomy. J Am Vet Med Assoc. 2016; 249(11): 1292-1300
- 12) Berent AC (2015). Interventional Management of Canine and Feline Benign Ureteral Obstructions. C Weisse, A Berent (Eds). Veterinary Image-Guided Interventions. (pp 309-335). Wiley-Blackwell: Hoboken, NJ.

Please email allyson.berent@gmail.com or chick.weisse@gmail.com if you have any questions or need additional information on the surgical implantation procedure of the SUB™ device.

ORDERING INFORMATION

SUB2.0™ KITS (1 KIT PER BOX)

Catalog Number	Description
SUB2-2001K for use in cats and small dogs	<ul style="list-style-type: none"> - 1 x Shunting SwirlPort™ w/Catheter Securement Boots (2) - 2 x 6.5F x 20cm Locking Loop Catheter w/Hollow cannula - 1 x 0.035" x 45cm J-tip Guidewire - 2 x 22G Posi-Grip Huber Needles - 1 x 22G Huber Needle Infusion Set - 1 x 18G Over-the-Needle Catheter - Accessories (extra boots (2), cuff (1), and sleeve (1)) - Surgical Instructions
SUB2-2002K for use in larger dogs	<ul style="list-style-type: none"> - 1 x Shunting SwirlPort™ w/Catheter Securement Boots (2) - 2 x 6.5F x 35cm Locking Loop Catheter w/Hollow cannula - 1 x 0.035" J-tip Guidewire - 2 x 22G Posi-Grip Huber Needles - 1 x 22G Huber Needle Infusion Set - 1 x 18G Over-the-Needle Catheter - Accessories (extra boots (2), cuff (1), and sleeve (1)) - Surgical Instructions
SUB2-3001K for use in cats and dogs, typically for obstructive neoplasia	<ul style="list-style-type: none"> - 1 x Shunting PantsPort™ w/Catheter Securement Boots (3) - 3 x 6.5F x 20cm Locking Loop Catheter w/Hollow cannula - 1 x 0.035" x 45cm J-tip Guidewire - 2 x 22G Posi-Grip Huber Needles - 1 x 22G Huber Needle Infusion Set - 2 x 18G Over-the-Needle Catheter - Accessories (extra boots (2), cuff (1), and sleeve (1)) - Surgical Instructions

SUB™ FLUSH KITS (5 KITS PER CASE)

Catalog Number	Description
SFK-22 for use with all shunting ports	<ul style="list-style-type: none"> - 1 x T-Port Connector - 1 x 3-way Stop-Cock - 1 x 22-Gauge Huber Point Needle - 1 x 3mL Syringe - 1 x 2.5mL Sterile Saline in 3mL Syringe - 1 x 2mL T-FloLoc™ in 12mL Syringe* - Instructions For Use (1 per Case of 5 Kits)
SFK-20 option for Swirl and Pants Shunting Ports	<ul style="list-style-type: none"> - 1 x T-Port Connector - 1 x 3-way Stop-Cock - 1 x 20-Gauge Huber Point Needle - 1 x 3mL Syringe - 1 x 2.5mL Sterile Saline in 3mL Syringe - 1 x 2mL T-FloLoc™ in 12mL Syringe* - Instructions For Use (1 per Case of 5 Kits)

NOTE: each flush kit is sterile packaged, suitable for sterile field use

**T-FloLoc™ can be ordered separately; call for details*